



**PATIENT**

Brutus the Cutest  
Armstrong

**SPECIES**

Canine

**BREED**

Chihuahua Mix

**SEX**

Male Intact

**AGE**

8 years

**WEIGHT**

12lbs

**INTERPRETED BY**

Maggie Machen Lamy,  
DVM, DACVIM  
(Cardiology)

**IMAGING PERFORMED BY**

Loetitia Saint-Jacques,  
LVT

**HOSPITAL NAME**

South Reno Veterinary  
Hospital

**REFERRING VET**

Dr. Schmitt

**INVOICE**

47084

**DATE**

2/2/26

**PRESENTING CLINICAL SIGNS**

History: Recheck echo. No exercise intolerance and excited to go on walks. Heart, Lungs and pulse: Grade 2/6 heart murmur audible on both sides with more of a swooshing sound on the right side. It is a base heart murmur and systolic. And lungs auscult and femoral pulses within normal limits.  
-Abnormal PE/Chem/CBC/UA Results (2/24/2026): Slight increased total protein, albumin, AST, cholesterol, phosphorus and magnesium CBC: Hemogram values upper end of normal. No significant finding Heartworm test antigen: No Antigen Detected Fecal: All undetected Urinalysis: Severe increased specific gravity.  
-Pertinent previous echo findings (3/2025 MML/LSJ): CVD B1. Mild MR, no LA or LVE, mild TR: 2.8m/s. LA: 1.8, LV: 2.7.

**RADIOGRAPHIC FINDINGS** \*NOTE: Images submitted for supplemental information only.

Normal cardiac silhouette. No obvious evidence of CHF.

**ELECTROCARDIOGRAPHIC FINDINGS**

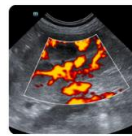
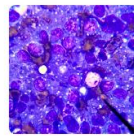
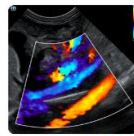
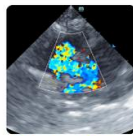
A six lead ECG is available at 25mm/s; 10mm/mV. The average heart rate is 150bpm. The rhythm is sinus in origin, with a p for every QRS complex and vice versa. The P wave morphology is positive with a normal dimension. Normal PR. The QRS morphology is positive with normal dimension. MEA is normal. A single APC is seen. No VPCs, pauses or other dysrhythmias observed. ECG diagnosis: Normal sinus rhythm with a single isolated APCs.

**ECHOCARDIOGRAM FINDINGS**

2D, m-mode, color flow and doppler imaging is available. Mild diffuse thickening of mitral valve leaflets with mild prolapse into the left atrial lumen. Moderate eccentric mitral regurgitation with slight left atrial dilation. Normal MR velocity. Normal LV diameter with adequate myocardial function. The tricuspid valve appears normal with mild to moderate tricuspid regurgitation. Velocity consistent with early pulmonary hypertension. Normal right atrial and ventricular diameter and morphology. The pulmonic and aortic valves are normal in morphology and mobility. Normal pulmonic and aortic outflow velocities with laminar flow. No obvious aortic or pulmonic insufficiency. No pericardial or pleural effusion noted. No obvious cardiac masses.

**CARDIAC CHART**

CANINE CARDIAC PARAMETERS	MR VMAX (m/s)	TR VMAX (m/s)	LA/AO (Boon method)	LA/AO (Heart Base; Swe)	FS (%)	EF (%)	EPSS (cm)
NORMAL PARAMETER	4.5-5.5	<2.7	1.3	<1.6	28-40	40-100	<0.6
PATIENT	6.1	3.0	NM	1.4	54	88	NM
CANINE CARDIAC PARAMETERS	HR (BPM)	AV VMAX (m/s)	PV MAX (m/s)	BODY WEIGHT (kg)	LA 2D short axis Base view (cm)	LVIDd Avg; 2D and m-mode short axis (cm)	LVIDs Avg; 2D and m-mode short axis (cm)
NORMAL PARAMETER	50-100	0.7-1.7	0.7-1.6	BELOW	BELOW	BELOW	BELOW
PATIENT	NM	1.8	1.1	5.4	1.9	2.6	1.2
*Normal chamber parameters expressed as a mean value (SD)				3	1.27 (5.3)	2.46 (2.46)	1.36 (5.5)



**PATIENT**

Brutus the Cutest  
Armstrong

**SPECIES**

Canine

**BREED**

Chihuahua Mix

**SEX**

Male Intact

**AGE**

8 years

**WEIGHT**

12lbs

**INTERPRETED BY**

Maggie Machen Lamy,  
DVM, DACVIM  
(Cardiology)

**IMAGING  
PERFORMED BY**

Loetitia Saint-Jacques,  
LVT

**HOSPITAL NAME**

South Reno Veterinary  
Hospital

**REFERRING VET**

Dr. Schmitt

**INVOICE**

47084

**DATE**

3/13/20

**BODY WEIGHT DEPENDENT PARAMETERS**

*\*Note: All measurements based upon multi-modal images and methods. An average value is reported.*

Adapted from June Boon, Veterinary Echocardiography, 1998  
Rishniw M and Hollis NE, J Vet Intern Med 2000; 14:429-435  
Hansson et al, Vet Rad and Ultrasound 2002  
Bonagura et al. Echocardiography: principles of interpretation, Vet Clin North Am 15:1177, 1995

5	1.40 (4.5)	2.74 (5.2)	1.60 (4.7)
10	1.50 (3.8)	3.27 (3.5)	2.06 (3.1)
15	1.83 (2.0)	3.71 (2.4)	2.43 (2.1)
20	2.02 (1.9)	4.14 (2.2)	2.80 (2.0)
25	2.18 (2.4)	4.48 (2.9)	3.10 (2.5)
30	2.33 (3.3)	4.83 (3.9)	3.39 (3.4)
35	2.48 (4.3)	5.17 (5.0)	3.69 (4.5)
40	2.62 (5.2)	5.48 (6.1)	3.96 (5.4)
50	2.88 (7.1)	6.07 (8.3)	4.46 (7.4)

**INTERPRETATION OF THE FINDINGS & FURTHER RECOMMENDATIONS**

Chronic degenerative valve disease persists with evidence of mild progression. Mild MR is now moderate; however, the LA and LV dimensions are essentially unchanged. Slight pulmonary hypertension has also developed, which is of unknown significance in a dog without respiratory disease. No additional issues are identified.

The ECG is largely normal with a sinus rhythm appreciated. A single isolated APC is identified, which is likely due to stress. No treatment is necessary.

Given these findings, it is reasonable to institute Pimobendan at this time. Continued assessment for progression is recommended, with a guarded prognosis (stage B2). That said, stability is certainly a good sign. Patient may be at risk for development of CHF, arrhythmias, and/or sudden death going forward.

Omega fatty acid supplementation and mild salt restriction may also be of some long-term benefit. Monitor for development of a progressive cough, labored breathing, exercise intolerance or collapse episodes.

Anesthetic risk remains mildly elevated. Cardiac protective drug choices (opioid/benzodiazepine premedication, Propofol or alfaxalone induction, iso or sevo gas) are recommended. Monitor for arrhythmias, hypotension, and hypoxia both intra and post-operatively and intervene as necessary. Judicious IV fluid rates are recommended to avoid fluid overload. Avoid heart rate stimulating drugs such as atropine unless clinically indicated.

**PLAN**

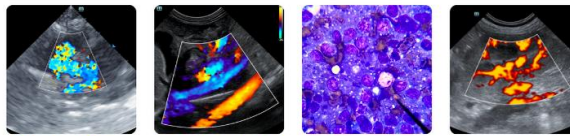
Baseline BP recommended every 6 months. Institute Pimobendan 0.25-0.3mg/kg PO q12h.

Recommend monitor for progression with a recheck echocardiogram in 6 months, sooner if any development of clinical signs.

Imaging performed by



PAWS  
Pawsonography@gmail.com  
530-786-8340



Clinical Sonography & Telectylogy  
Educational Teleconsultation Services™

SonoPath

FOSTERING THE ART OF VETERINARY MEDICINE™

SonoPath.com info@sonopath.com 1.800.838.4268

**PATIENT**

Brutus the Cutest  
Armstrong

**SPECIES**

Canine

**BREED**

Chihuahua Mix

**SEX**

Male Intact

**AGE**

8 years

**WEIGHT**

12lbs

**INTERPRETED BY**

Maggie Machen Lamy,  
DVM, DACVIM  
(Cardiology)

**IMAGING PERFORMED BY**

Loetitia Saint-Jacques,  
LVT

**HOSPITAL NAME**

South Reno Veterinary  
Hospital

**REFERRING VET**

Dr. Schmitt

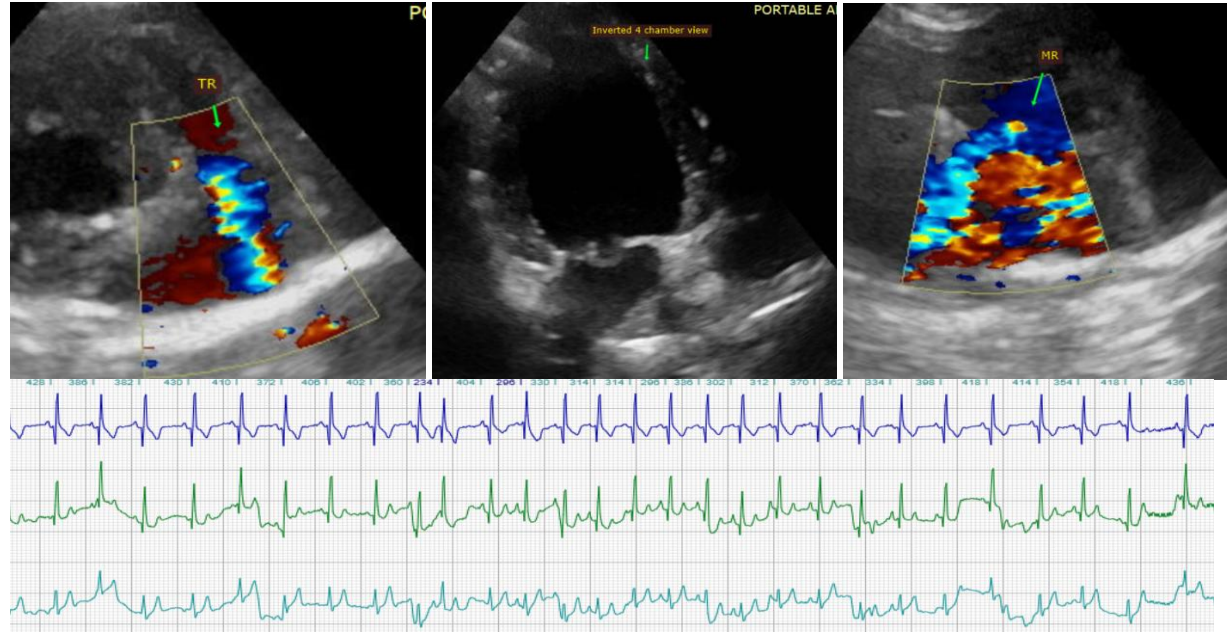
**INVOICE**

47084

**DATE**

3/13/20

**IMAGES**



The information and recommendations provided are based on the images presented by the referring veterinarian. No evaluation can be communicated regarding pathology that was not visible in the image/video clips provided.

Thank you for this referral. This report was generated using transcription software, and minor dictation errors may be present. If the clinical or image interpretation does not parallel your findings or if I can be of any further assistance, please contact me.

**Maggie Machen Lamy, DVM**  
**Diplomate of the American College of Veterinary Internal Medicine (Cardiology)**  
info@sonopath.com